

THE JOURNAL OF BONE & JOINT SURGERY

J B & J S

This is an enhanced PDF from The Journal of Bone and Joint Surgery

The PDF of the article you requested follows this cover page.

A NEW METHOD OF CURING INVETERATE SOFT CORNS BETWEEN THE TOES

A. M. PHELPS

J Bone Joint Surg Am. 1894;s1-6:238-239.

This information is current as of November 9, 2009

Reprints and Permissions

Click here to [order reprints or request permission](#) to use material from this article, or locate the article citation on jbjs.org and click on the [Reprints and Permissions] link.

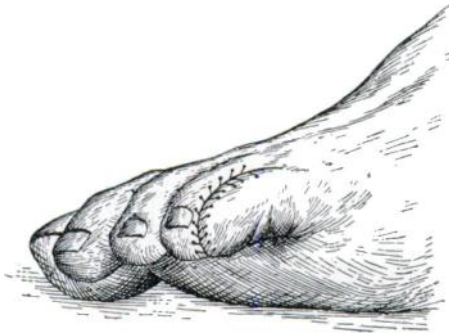
Publisher Information

The Journal of Bone and Joint Surgery
20 Pickering Street, Needham, MA 02492-3157
www.jbjs.org

A NEW METHOD OF CURING INVETERATE SOFT
CORNS BETWEEN THE TOES.

By A. M. PHELPS, M.D.,
NEW YORK.

WE all frequently meet with cases of soft corn, occurring particularly in the working classes, between the toes. They are extremely painful, crippling the patient and rendering life almost unendurable. These cases come to the hospital and ask to have the toes amputated. Such corns are usually treated conservatively, and are cured, but immediately relapse. Deep sloughing ulcers are frequently seen.



A simple procedure which I have followed many times during the past few years answers admirably and saves the toe. It consists in removing all of the soft tissues on the inner side of two of the toes, removing the corn, and stitching the two toes together, as seen in the figure. This procedure does not in the least impair the usefulness of the foot; whereas the removal of the toe must necessarily do so to a certain extent.

Patients upon whom I have operated in this manner have expressed themselves as entirely satisfied, and I am certain that if I had a soft corn that caused me much trouble I would have no hesitancy in having the operation performed, and the toes "webbed." The nail of the little toe should be removed.